

# ECG Fundamentals

53yF with history of smoking and hyperlipidemia with chest pain for the past 2 hours.

HR: 95      BP: 130/110

RR: 18      O2 Sat: 96%

## What is your interpretation of the ECG?

History/Clinical Picture

P Waves

Rate

Q/R/S Waves

Rhythm

T Waves

Axis

U Waves

PR Interval

QRS Width

ST Segment

QT Interval

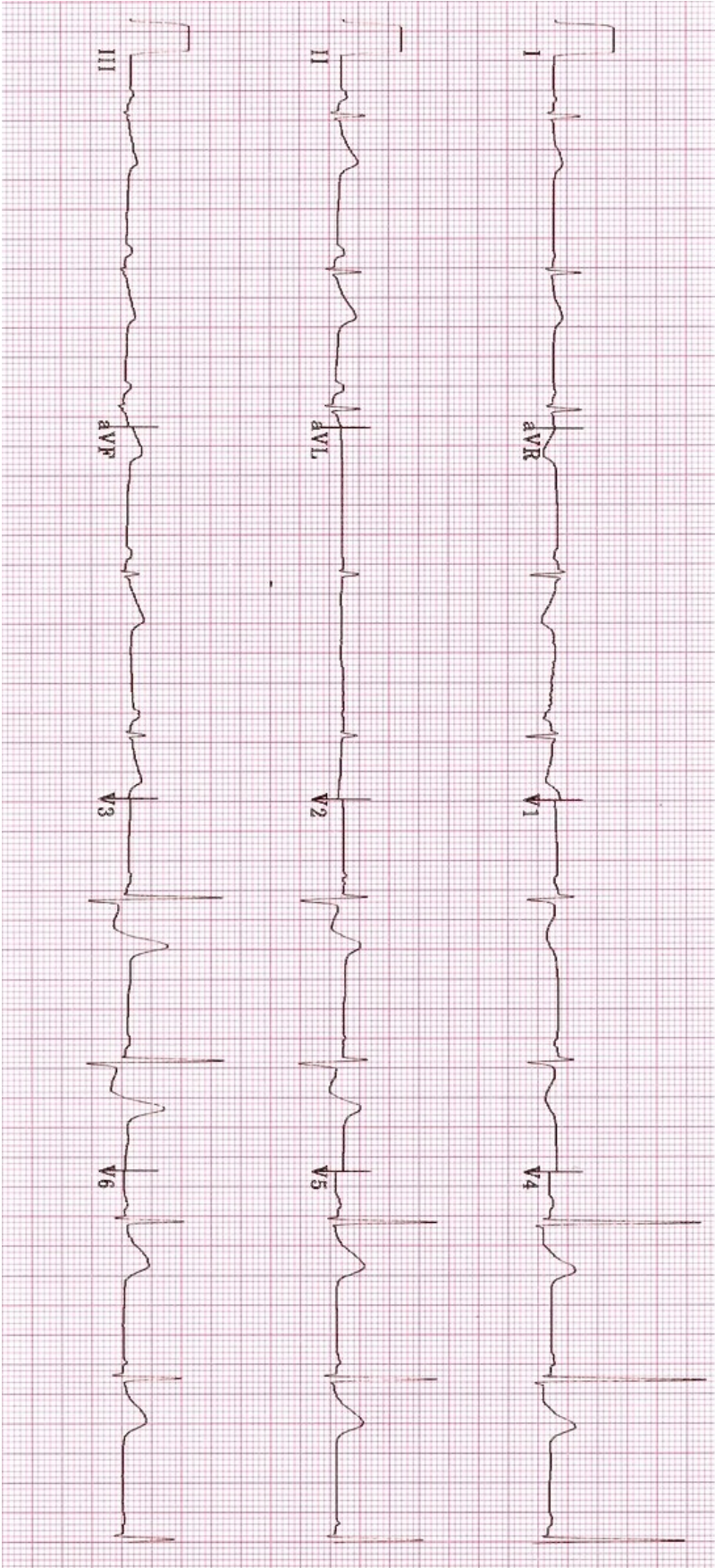
## What are the electrocardiographic manifestations of this type of MI?

### Resources Links:

[Life in the Fast Lane](#)

[Dr. Steve Smith's Blog](#)

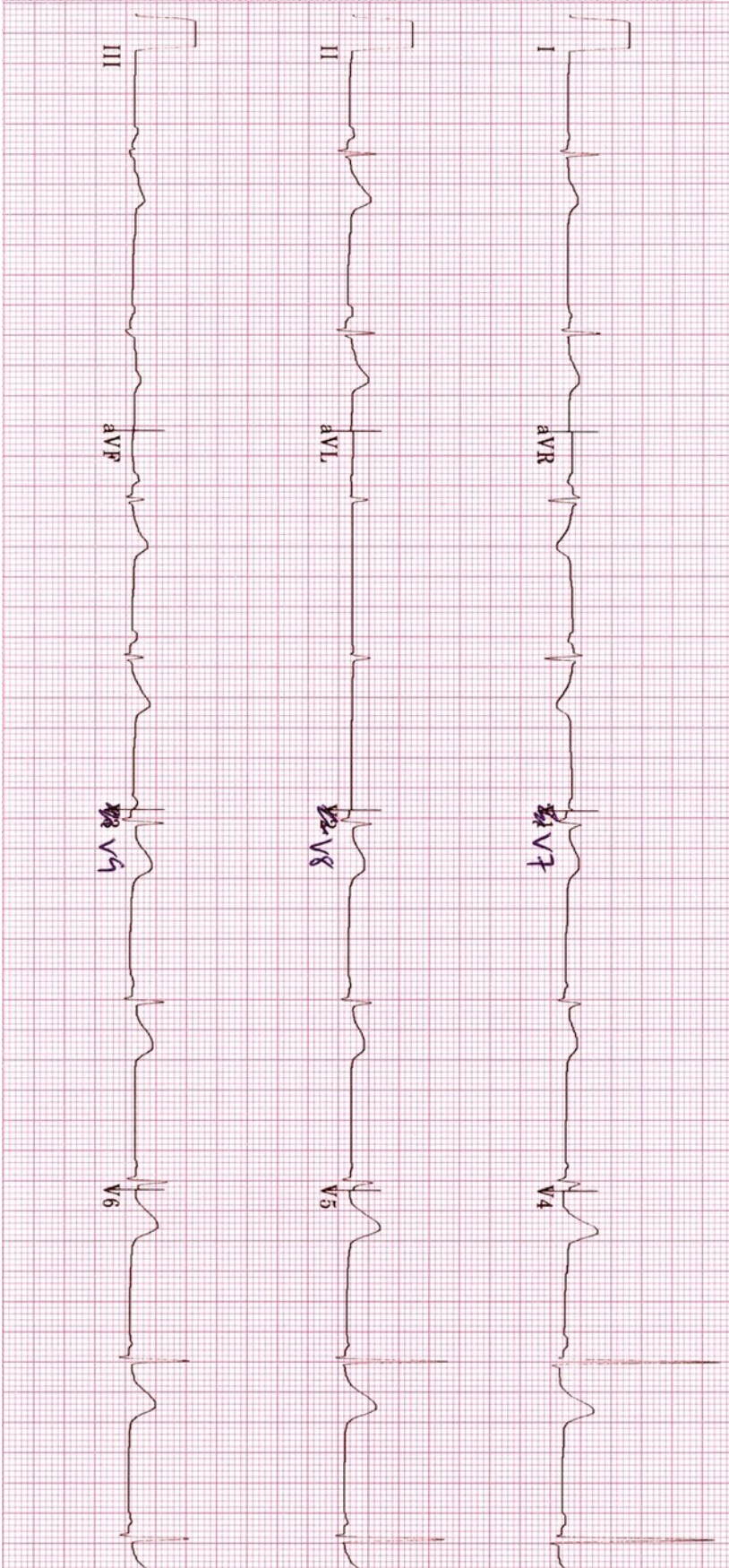
# Triage ECG



Courtesy of Edward Burns of [Life in the Fast Lane](#)

[Creative Commons License](#)

# Repeat ECG



Courtesy of Edward Burns of [Life in the Fast Lane](#)

[Creative Commons License](#)