

# EKG Fundamentals

21yM with no significant PMHx complaining of chest pain. No known family history as the patient is adopted.

HR: 120    BP: 100/60

RR: 28    O2 Sat: 88%

## What is your interpretation of the EKG?

Clinical Picture

P Waves

PR Interval

Rate

Q/R/S Waves

QRS Width

Rhythm

T Waves

ST Segment

Axis

U Waves

QT Interval

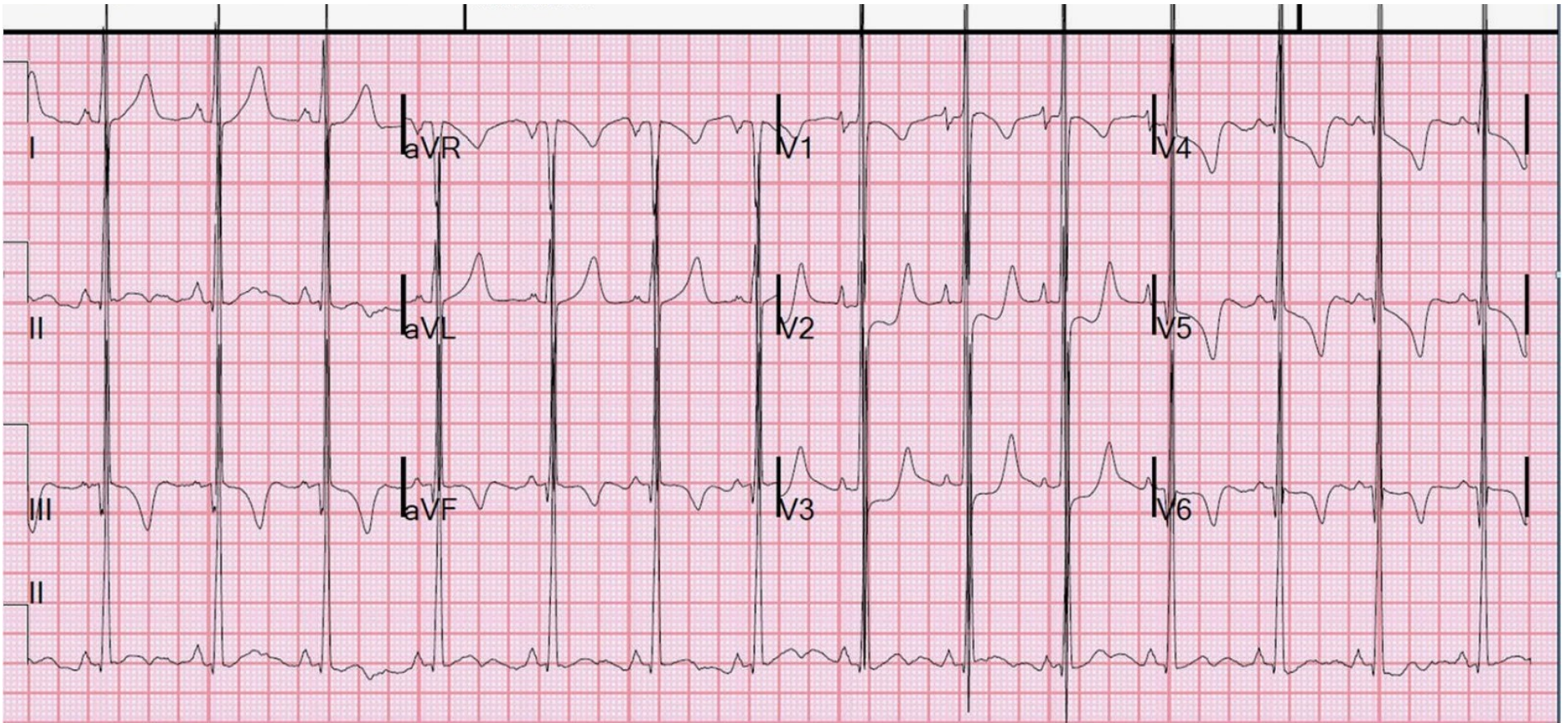
What condition that affects cardiac conduction is frequently comorbid with the condition this patient has?

## Resource Links:

[Life in the Fast Lane](#)

[Dr. Smith's ECG Blog](#)

# Triage EKG



Original Source: Dr. Steve Smith & [Dr. Smith's ECG Blog](#)

Created by William Burns, MD