

# EM EKG Fundamentals

5 year-old boy with no past medical history presents with his grandfather with complaint of N/V/D. The nurse mentioned lots of PVCs on the monitor so you get an ECG.

HR: 120      BP: 90/50

RR: 22      O2 Sat: 97%

## What is your interpretation of the EKG?

History/Clinical Picture

Rate

Rhythm

Axis

P Waves

Q/R/S Waves

T Waves

U Waves

PR Interval

QRS Width

ST Segment

QT Interval

Resource Links: [Life in the Fast Lane](#)

[Dr. Steve Smith's Blog](#)

# Triage EKG

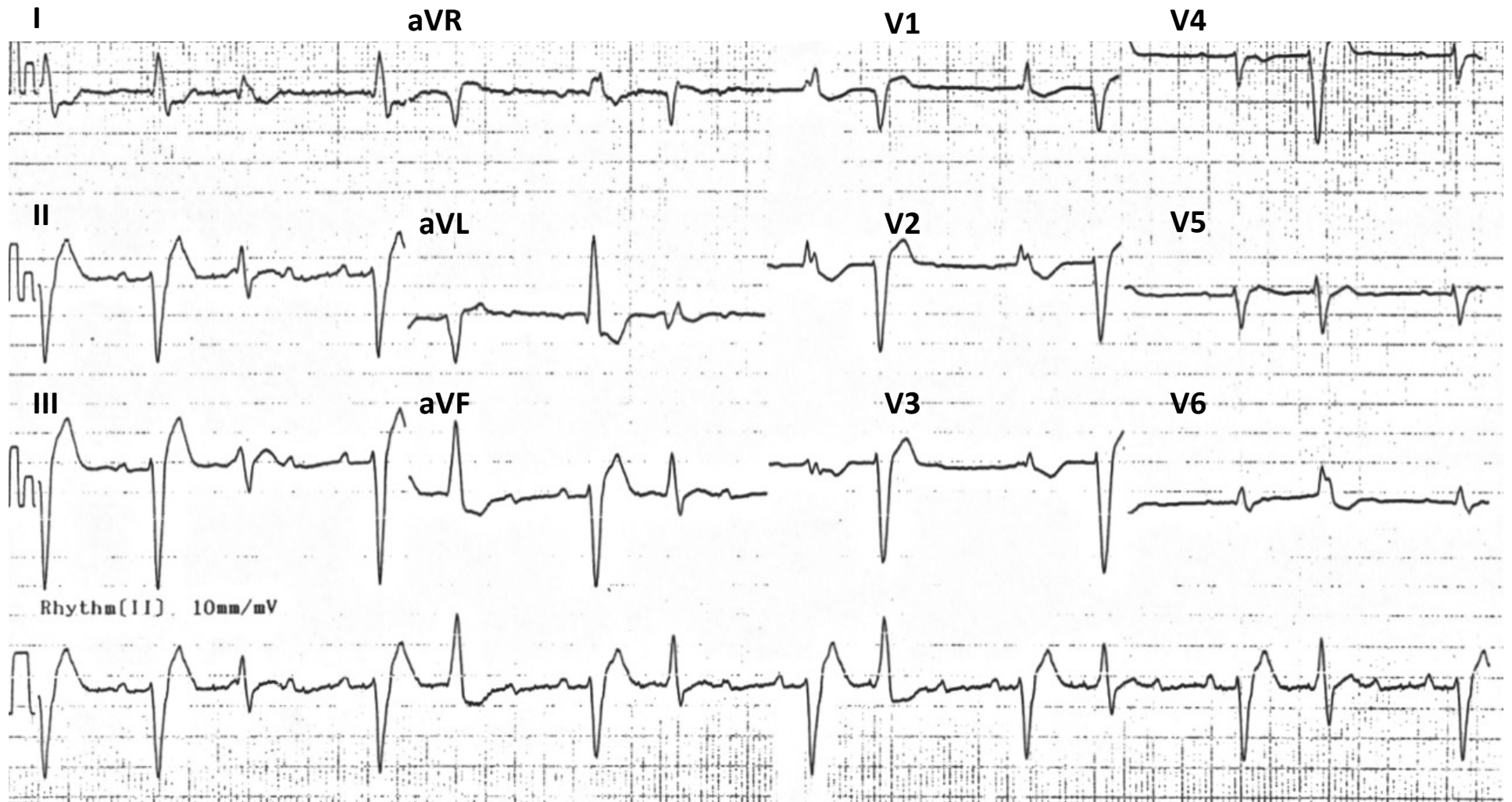


Image Adapted From Edward Burns of [Life in the Fast Lane](#)  
[Creative Commons License](#)