



# Foundations EKG I - Unit 1 Summary

The accurate diagnosis of ST elevation myocardial infarction (STEMI) is one of the most time critical duties in the practice of EM. Diagnosis is not always easy so guidelines can help but realize **there may be local, regional, and national variation.**

The most recent US-focused consensus on STEMI criteria:

- **> 1mm of new STE above the J-point in two contiguous leads (except V2-3)**

- **V2-3 Specifics**

Men: > 2mm of new STE above the J-point

Women: > 1.5mm of new STE above the J-point

- **Left Bundle Branch Block**

The presence of a LBBB complicates the interpretation of STEMI and requires application of the Sgarbossa and Modified Sgarbossa criteria that are well described by this CORE EM [blog post](https://coreem.net/core/stemi-lbbb/) (<https://coreem.net/core/stemi-lbbb/>).

Patients with a truly new LBBB resulting from an occluded artery are usually very sick.

The most recent international consensus guideline The 3rd Universal Diagnosis of Acute MI provides the following specific criteria for posterior and right ventricular MI:

## **Posterior Lead (V7-9)**

> 0.5mm of new STE above the J-point. **Except** in men under 40: > 1mm of new STE above the J-point

## **Right Sided Lead (V3R & V4R)**

> 0.5mm of new STE above the J-point. **Except** in Men under 30: > 1mm of new STE above the J-point

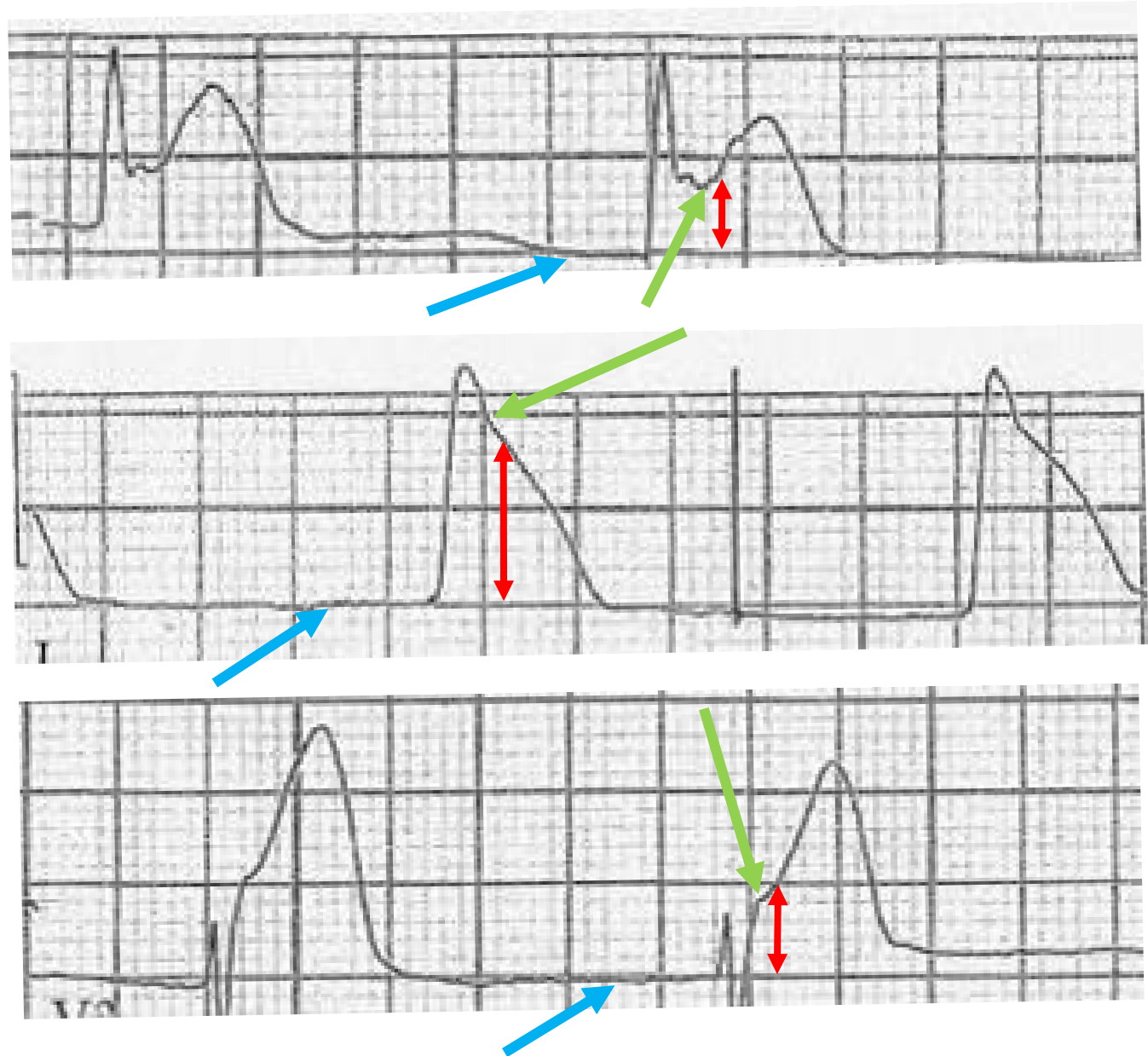
# Identifying the J-Point & Measuring ST Elevation

The **J point** marks the start of ventricular repolarization at the end of the QRS complex and the beginning of the ST Segment.

It is the landmark that guides ST elevation (STE) measurement.

The morphologic abnormalities associated with STEMI can make it difficult to identify the J-point. On the right are several examples with the **J-point (Green →)** highlighted.

Measure STE from isoelectric line to J point. The **isoelectric line** is best defined as the segment between the T and P waves (aka TP segment) as the heart is electrically silent. The **isoelectric line (Blue →)** and **STE (Red →)** are highlighted.



# Localization of Myocardial Infarction

When the STEMI guidelines refer to contiguous leads they are referring to the territorial regions of the heart that the leads generally represent. For example, any combination of pathologic STE in at least 2 leads that are right next to each other (i.e. contiguous) in the septal/anterior/lateral leads V1/V2/V3/V4/V5/V6 would rule in STEMI but STE in V1 & V6 would not because they are not contiguous. Along the same lines, STE in II & III would rule in STEMI but I and aVR would not. Finally, any combination of II, III, and aVF with pathologic STE would rule in STEMI. For a deeper review of contiguous and reciprocal leads please see this post by Tom Boughillet of EMS 12 Lead—[goo.gl/3zgZGu](http://goo.gl/3zgZGu).

I—Lateral/High Lateral	aVR—only Right Facing Lead	V1—Septal	V4—Anterior
II—Inferior	aVL—Lateral/High Lateral	V2—Septal	V5—Lateral
III—Inferior	aVF—Inferior	V3—Anterior	V6—Lateral

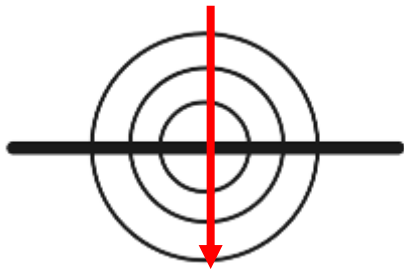
# Localization of Myocardial Infarction Continued

The 12 lead EKG is a great tool, however, it is imperfect. For example, ST depression (STD) can either represent a reciprocal change from ST elevation on the opposite side of the heart or ischemia without associated STE. The causes of reciprocal change are beyond the scope of this summary but essentially they are the mirror image of the STEMI on the opposite side of the heart. The standard 12 lead has no posterior leads so an isolated posterior STEMI would not cause STE unless posterior leads were placed. Instead **the only evidence of posterior STEMI could be reciprocal STD in V1-3**. This table shows typical reciprocal change patterns. It is important to realize that **reciprocal changes are not always present in STEMI** and also that **reciprocal changes may be earliest sign of STEMI!**

Infarction Distribution	ST Elevation	ST Depression (Reciprocal Change)
Anterior Wall	V1—V4, I, aVL	II, III, & aVF
Lateral Wall	I, aVL, V5, V6	V1 Also Right sided leads
Inferior Wall	II, III, aVF	V1—V4, I, aVL
Right Ventricle	III > II and usually V1 > V2 (V2R, V3R, V4R)	V2
Posterior Wall	Posterior Leads V7, V8, V9	V1-V3 (often tall R waves)

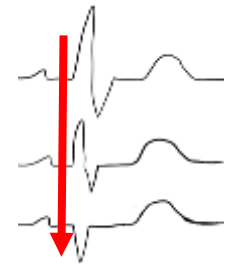
# Other EKG Changes Suggestive of Ischemia

Although ST Elevation is likely the best known EKG change associated with ischemia there are many overt and subtle changes:

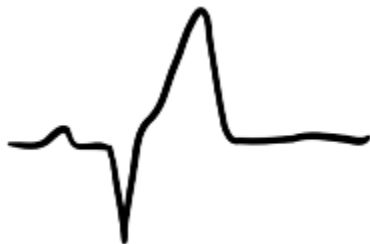

**T Wave Inversion (TWI)**—The best way to think about TWI is a loss of T wave amplitude (height above the isoelectric line) because before a T Wave becomes inverted it first loses amplitude until it is flat and then finally inverts. Loss of amplitude and flattening can represent early ischemia. Finally, don't fall into the trap of attributing localization to T waves because, unlike ST elevation, T wave changes do not localize.

**R Wave Amplitude**—Loss of R wave amplitude should be concerning for active ischemia or prior myocardial infarction in the right clinical scenario. In fact, a complete loss of R wave amplitude results in in a Q wave. This finding can certainly be confounded by lead placement, effusion, or a change in habitus however so it is always reasonable to repeat the EKG.



**ST Depression**—Like ST elevation, ST depression (STD) is best measured from the isoelectric line. Occasionally, STD is very significant and easy to measure, but much more frequently it is very minimal and difficult to measure. Avoid the temptation to ignore subtle ST depression. Finally, like T wave changes don't forget that STD doesn't localize.



**Hyperacute T Waves**—T waves that are **much** larger than their respective R waves (particularly when they are preceded by Q wave or near Q waves) should be very concerning for ischemia. Early repolarization can be difficult to distinguish from hyperacute T waves so a good history and comparison to old EKGs if available is critical.

Ischemia is usually associated with a **prolonged QT interval** and patients are more likely to be **bradycardic** than tachycardic. These changes should only trigger suspicion and are neither sensitive or specific for ischemia.