

# Foundations EKG II - Unit 11, Case 43



*5 year-old boy with no PMH presents with his grandfather, whom he is visiting, complaining of N/V/D and blurred vision. The nurse mentioned lots of PVCs on the monitor so you get an ECG.*

HR: 120      BP: 90/50

RR: 22      O2 Sat: 98%

## **What is your interpretation of the EKG?**

History/Clinical Picture

Rate

Rhythm

Axis

P Waves

Q/R/S Waves

T Waves

U Waves

PR Interval

QRS Width

ST Segment

QT Interval

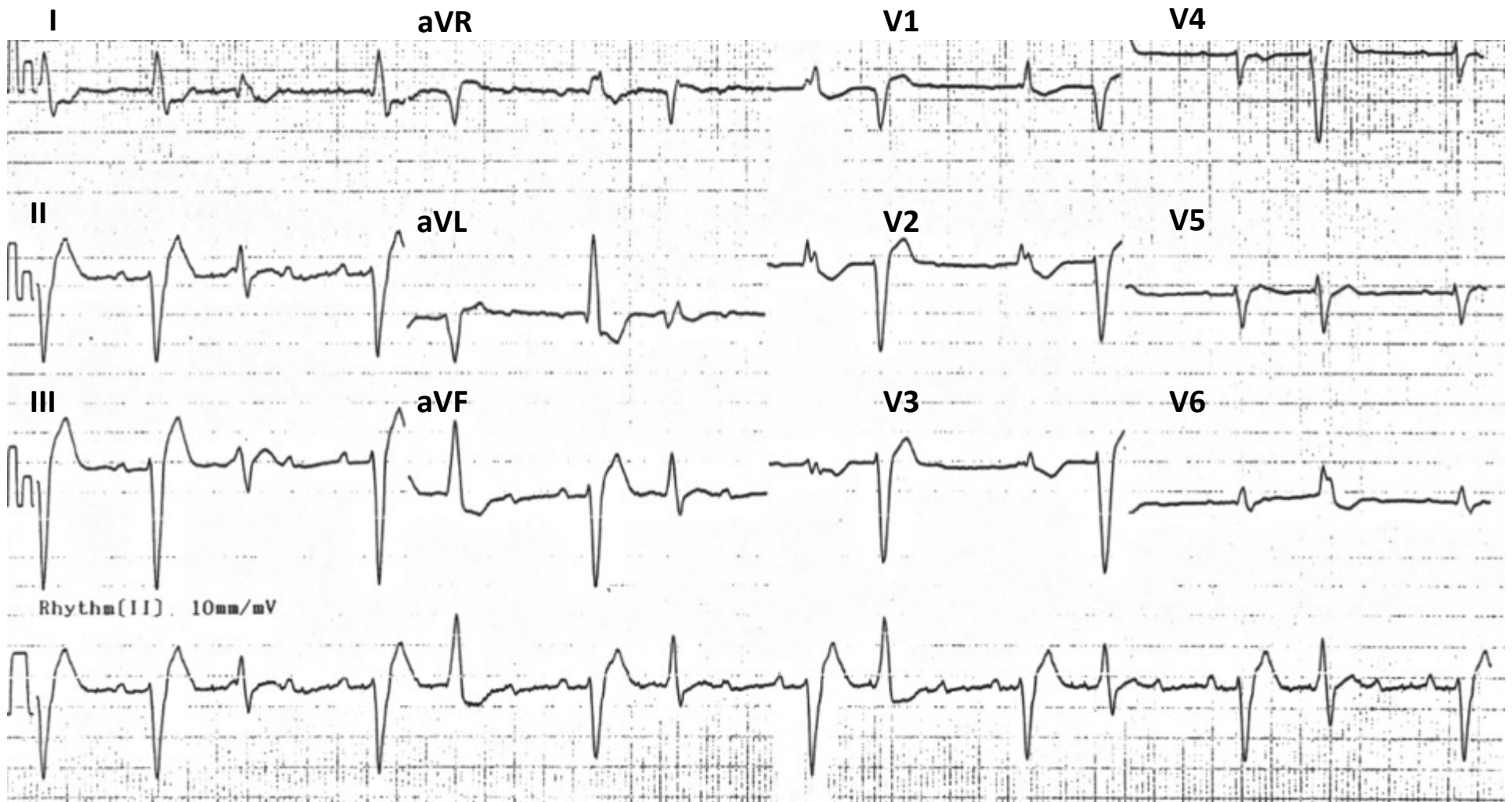
**Putting the clinical history together with the ECG, what do you think is going on with this patient?**

**What other ECG findings are found with this pathology?**

**What labs do you want immediately?**

**What treatment would you initiate?**

# Triage EKG—Unit 11, Case 43



Courtesy of Edward Burns of [Life in the Fast Lane](#)

[Creative Commons License](#)